

Transepidermal Retinoic Acid Delivery Using Ablative Fractional Radiofrequency Associated With Acoustic Pressure Ultrasound for Stretch Marks Treatment

Maria Cláudia Almeida Issa, MD, PhD,^{1*} Luiza Erthal de Britto Pereira Kassuga,^{1†}
 Natalia Stroligo Chevrant,^{1†} Livia do Nascimento Barbosa, MSc,¹ Ronir Raggio Luiz, PhD,²
 Luciana Pantaleão, MD,³ Enoi Guedes Vilar, MD,³ and Mayra Carrijo Rochael, MD, PhD³

¹Dermatology, Fluminense Federal University, Praia de Icarai, 139/702 Niteroi, Rio de Janeiro, CEP 24230-001, Brazil

²Institute of Public Health Studies, Federal University of Rio de Janeiro, Rio de Janeiro, Brazil

³Pathology, Fluminense Federal University, Niterói, Rio de Janeiro, Brazil

Background: Striae distensae (SD) treatment still remains a therapeutic challenge to dermatologists. Ablative fractional laser and radiofrequency (RF) enhance skin-drug permeability for SD treatment.

Objective: To clinically evaluate the efficacy and safety as well as patient's satisfaction in relation to a method using ablative fractional RF associated with retinoic acid 0.05% cream and an acoustic pressure wave ultrasound (US) in patients with alba-type SD on the breast.

Methods and Materials: Eight patients with alba-type SD on the breast were treated with three step procedure: (1) fractional ablative RF for skin perforation; (2) topical application of retinoic acid 0.05% on the perforated skin; and (3) US was applied to enhance the retinoic acid penetration into the skin. Other eight patients with alba-type SD on the abdominal area were submitted to RF treatment isolated without retinoic acid or US. Three of them were submitted to skin biopsies.

Results: Three patients with SD on the breast area improved from "severe" to "moderate;" two patients improved from "severe" to "mild;" two patients from "moderate" to "mild;" one patient from "marked" to "mild." Clinical assessment demonstrated significant improvement in the appearance of SD in all patients treated with RF associated with retinoic acid 0.05% cream and US ($P = 0.008$), with low incidence of side effects and high level of patient's satisfaction. Among the patients treated only with RF, two patients improved from "severe" to "marked;" one patient from "marked" to "moderate;" and one patient improved from "marked" to "mild." Four patients did not show any sort of improvement. Clinical assessment demonstrated no significant improvement in the appearance of SD treated with RF isolated with low incidence of side effects, but low-level of patient's satisfaction.

Conclusion: Ablative fractional RF and acoustic pressure US associated with retinoic acid 0.05% cream is safe and effective for alba-type SD treatment. *Lasers Surg. Med.* © 2012 Wiley Periodicals, Inc.

Key words: fractional resurfacing; percutaneous administration; striae distensae

INTRODUCTION

Stretch marks or striae distensae (SD) are atrophic dermal scars with overlying epidermal atrophy, causing significant cosmetic concern. There is a lot of controversy over their pathophysiology and a variety of treatment modalities have been attempted, otherwise no single modality has been far more consistent than the rest [1,2].

Recent SD, striae rubra, can be treated with topical products such as tretinoin and glycolic acid with variable results. These treatments, however, work poorly on mature SD, striae alba, in which ablative and nonablative lasers can be an option [3–5]. The new technology using ablative fractional lasers and/or ablative fractional radiofrequency (RF) can promote skin remodeling with a short downtime and good result [2,6,7]. However special measures are necessary when using lasers for darker skin phototypes [8–10].

Transepidermal drug delivery (TED) using ablative fractional technology is a new concept in Dermatology, in which fractioned ablation disrupts the stratum corneum, overcoming the barrier presented for drug penetration. Different techniques using fractional Er:YAG lasers and CO₂ lasers can be used with the aim to increasing the

[†]Resident Physician

Conflicts of interest Disclosures: All authors have completed and submitted the ICMJE Form for Disclosure of Potential Conflicts of Interest and have disclosed the following: Maria Cláudia Almeida Issa: Consultant Doctor—Alma Lasers. Researches: Provided the medicaments.

*Corresponding to: Maria Cláudia Almeida Issa, MD, PhD, Dermatology, Fluminense Federal University, Praia de Icarai, 139/702 Niteroi, Rio de Janeiro, CEP 24230-001, Brazil.

E-mail: maria@mariaissa.com.br

Accepted 18 November 2012

Published online in Wiley Online Library

(wileyonlinelibrary.com).

DOI 10.1002/lsm.22105

efficacy of drugs topically applied in many different dermatoses [11,12]. Similar to the ablative lasers, ablative fractional RF technology can disrupt the skin, causing micro-channels in the epidermis, and alters the skin permeability.

In this prospective study we evaluated the safety and efficacy of transepidermal delivery of retinoic acid (0.05%) cream using ablative fractional RF and acoustic pressure wave ultrasound (US) technology, for the treatment of SD on the breast.

MATERIALS AND METHODS

Sixteen patients clinically diagnosed with alba-type SD were enrolled to the study. All of them had not been previously treated with any medical or surgical methods. The study was approved by the local Ethic Committee in 2009.

Eight healthy women patients with SD on breast area, age ranging between 18 and 28 years old, phototypes III–VI, and SD history ranging from 2 to 17 years (Table 1) were involved in the treatment proposed in this study, using RF + retinoic acid cream + US. Another eight healthy women patients with SD in the abdominal area, age ranging between 28 and 45 years old, phototypes III–VI, and SD history ranging from 3 to 20 years (Table 2) were treated with RF isolated.

All 16 patients were assessed at baseline with subjective measurements of the disease made by three different non-treating physicians on a five-point analog scale (0 = none; 1 = mild; 2 = moderate; 3 = marked, and 4 = severe) [13]. The same scale was used at the end of treatment and 30 days after the last session. The patients were recruited for another assessment 18 months after treatment.

Scoring Physicians Were Blinded to FotOS

Three patients with SD on abdominal area were submitted to skin biopsies in the lower abdomen for histopathological evaluation with the aim to understanding

the mechanism of action of the RF and RF associated with US better. The procedures were done as follows: (1) RF + dye (Nankim ink) + biopsy just after procedure; (2) RF + dye (Nankim ink) + US + biopsy just after procedure; and (3) RF + dye (Nankim ink) + US + biopsy 30 minutes after procedure. In all cases, a drop of dye (Nankim ink) was used as a contrast agent so that it could be observed in the histopathological analysis. Skin biopsies were done with 5 mm punch and the excised skin was fixed in 10% formalin and embedded in paraffin. Three dermatopathologists masked at the time of sampling evaluated the histopathological results (Table 3).

Exclusion criteria included patients with pacemaker, metallic prosthesis in the area to be treated, pregnancy, breast feeding, localized or systemic infection, immunosuppression, oral isotretinoin within the past 12 months and patient undergoing any other treatment for at least 3 months before the trial beginning. Patients signed the informed consent form and to allow photos for presentation.

The eight patients with SD on the breast underwent four treatments with ablative fractional RF and low frequency acoustic pressure US distinct technology (Legato System - ALMA LASERS Ltd.). Treatments were spaced every 4 weeks. Before each session, the treatment area was cleaned with aqueous chlorhexidine. At first, skin perforation was achieved by ablative fractional RF module (Pixel roller; in-motion tip) applied with four sequential passes (two crosses) on the SD affected skin. Typically, treatment parameters were set at 45 W. Immediately after ablative fractional RF procedure, retinoic 0.05% cream—0.5 g/area (Vitanol-A[®], Stiefel), was topically applied on the skin surface (10 cm × 10 cm area). Then, the acoustic pressure US module was applied with the following parameters: 50 Hertz—rate of sonotrode vibration per second and 80%—US power intensity, for 2 minutes at each 10 cm × 10 cm grid area (Fig. 1a–c).

The patients with SD on the abdomen, treated with RF isolated, underwent four treatments with the same

TABLE 1. Patients With SD on the Breast Treated With RF + Retinoic Acid + US: Demographics and Clinical Evaluation Before Treatment, 30 days and 18 months After Treatment

Patient	Phototype	Duration	Striae distensae	Severity	Severity	Severity
		Striae distensae (yrs)	Type	Baseline Assessment	Assessment After 30 days	Assessment After 18 months
1	III	2	ALBA	2	1	1
2	III	7	ALBA	4	2	2
3	III	13	ALBA	4	1	1
4	III	6	ALBA	3	1	1
5	III	10	ALBA	4	1	1
6	VI	17	ALBA	4	2	2
7	III	3	ALBA	4	2	2
8	III	4	ALBA	2	1	1

0 = none; 1 = mild; 2 = moderate; 3 = marked, 4 = severe.

TABLE 2. Patients With SD on the Abdomen Treated With RF Isolated: Demographics and Clinical Evaluation Before Treatment, 30 days and 18 months After Treatment

Patient	Phototype	Duration	Striae distensae	Severity	Severity	Severity
		Striae distensae (yrs)	Type	Baseline Assessment	Assessment After 30 days	Assessment After 18 months
1	III	4	ALBA	3	3	3
2	III	20	ALBA	3	1	1
3	III	18	ALBA	3	3	3
4	IV	3	ALBA	4	3	3
5	IV	15	ALBA	3	2	2
6	III	20	ALBA	3	3	3
7	III	5	ALBA	4	3	3
8	IV	10	ALBA	4	4	4

1 = mild; 2 = moderate; 3 = marked, 4 = severe.

ablative fractional RF, but not with retinoic acid cream nor with the acoustic pressure US. Treatments were spaced every 4 weeks. Before each session, the treatment area was cleaned with aqueous chlorhexidine. The ablative fractional RF module (Pixel roller; in-motion tip) was applied with four sequential passes (two crosses) on the SD affected skin. Typically, treatment parameters were set at 45 W.

After procedure, all patients were advised to moisturize the skin and to avoid sun exposure. They were submitted to dermatologic exam 24–72 hours and 15 days after each session and 30 days after the last session.

Ablative Fractional RF Module

The ablative fractional RF module is incorporated in a unipolar RF-based handpiece. The handpiece receives RF energy, which includes a roller assembled in six cogs with 50 pins on the radial surface of each cog. An array of (tiny metal pins) protrusions is disposed on the radial surface of the roller, configured to cause multiple electrical discharges to be generated in response to the RF electrical

power in a space between the protrusions and the skin as the roller is advanced over the skin's surface. The ablative micro-plasma RF energy stimulates micro-sparks between the skin surface and the RF protrusions, producing holes of 100–150 μm in depth (evaporation + thermal) and 80–120 μm in diameter (width) on the skin surface.

Acoustic Pressure US Module

The acoustic pressure module comprised of a transducer, sonotrode and a distal (hollow) horn. It is applied perpendicular to the surface of the skin and with continuous contact with the skin surface in a circular (concentric–eccentric) in-motion movement of the sonotrode. The distal surface of the horn creates vibrational cycles (“push–pull”) on the medication (retinoic acid) and on the surface of the skin to promote the delivery of the retinoic acid. The mode of operation is based on mechanical (acoustic) pressure and torques by propagation of US wave via the sonotrode to the distal horn and the creation of hammering-like effect (push–pull) in the thin layer between the medication, the treated skin and the operative

TABLE 3. Patient Demography, Procedures, and Histopathological Results

Patient	Phototype	Duration	Striae distensae	Procedure/period before biopsy (minutes)	H&E stain
		Striae distensae (yrs)	Type		
1	IV	15	ALBA	RF + black ink/1 minute	Micro-channels inside epidermis + ink along skin surface
2	IV	12	ALBA	RF + black ink + US/1 minute	Micro-channels inside epidermis + ink mainly located inside them
3	IV	20	ALBA	RF + green ink + US/30 minutes	Micro-channels inside epidermis + ink located in dermo-epidermal junction

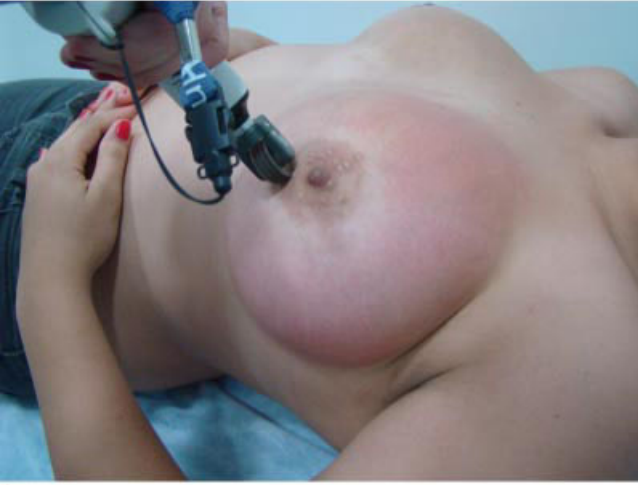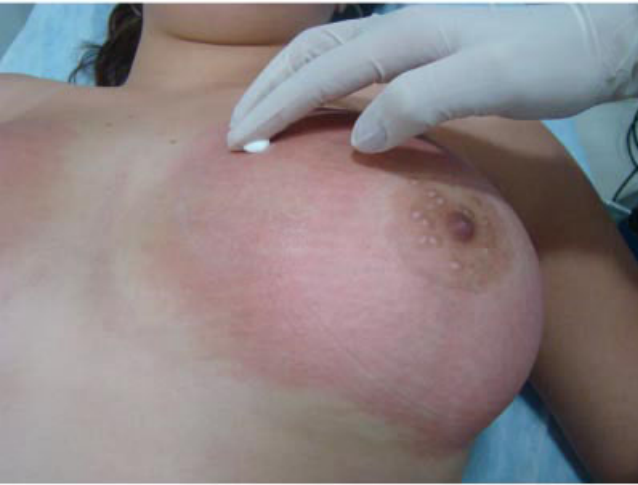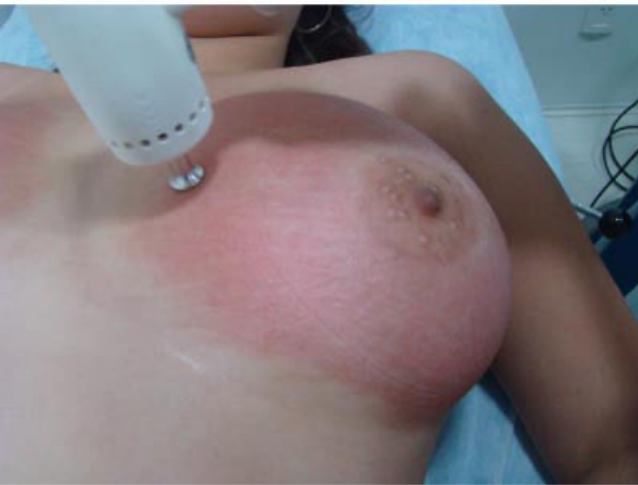a**b****c**

Fig. 1. **a:** Patient 3—applying ablative fractional radiofrequency (RF). **b:** Patient 3—applying tretinoin 0.05% cream. **c:** Patient 3—applying acoustic pressure ultrasound (US).

surface of sonotrode. This layer should contain a delivered medication, which is chosen according to the disease to be treated. The hammering effect by the sonotrode creates the transport of the delivered drugs/material to the area of preliminary RF perforated skin and increasing of the penetration of the drug into the skin.

Side effects (erythema, edema, crust, blister, dyschromia, and scar) and pain were evaluated by the same investigators on a three-point scale (0 = absent, 1 = mild, 2 = moderate, 3 = severe) [13]. Patients were questioned about their improvement at the end of the treatment, 30 days after the last session, according to a quartile scale of improvement was used: 0 = no improvement; 1 = 1–25%—minimal

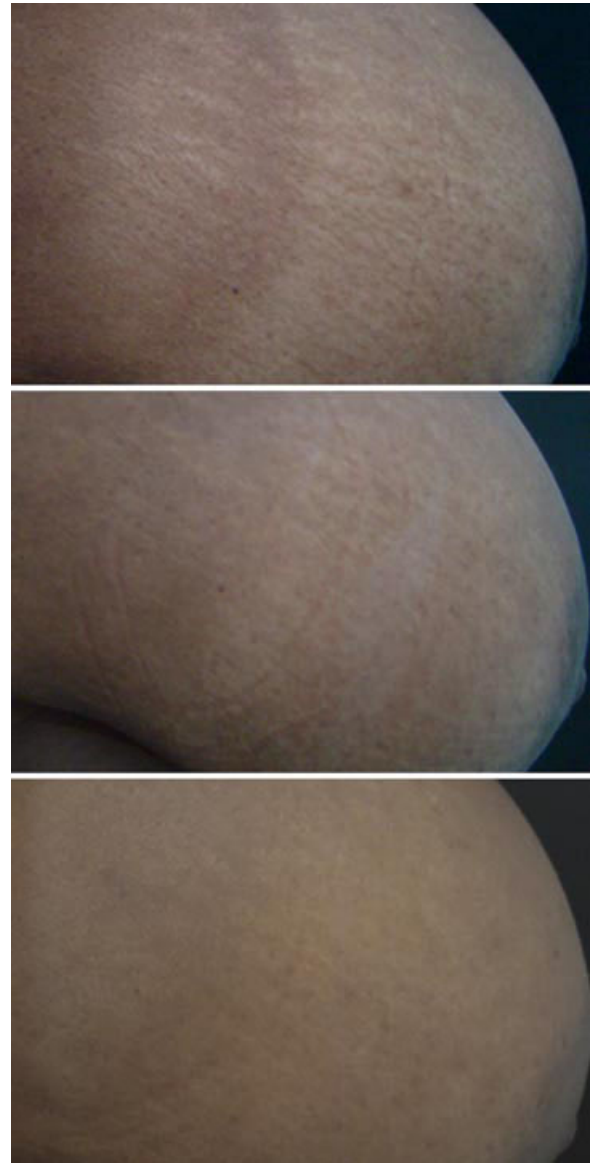

Fig. 2. **a:** Patient 6—before treatment. **b:** Patient 6—30 days after four sessions (RF + retinoic acid + US). **c:** Patient 6—18 months after four sessions (RF + retinoic acid + US).

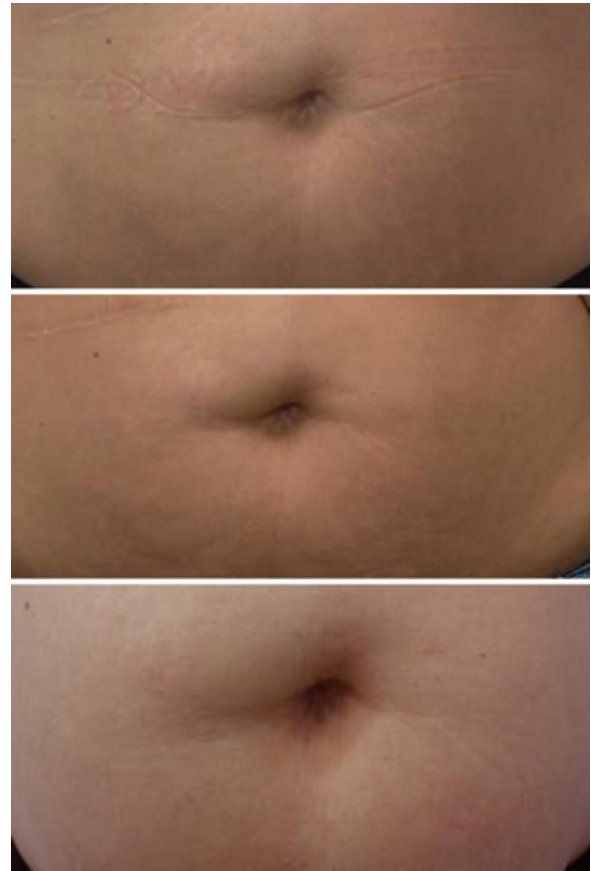
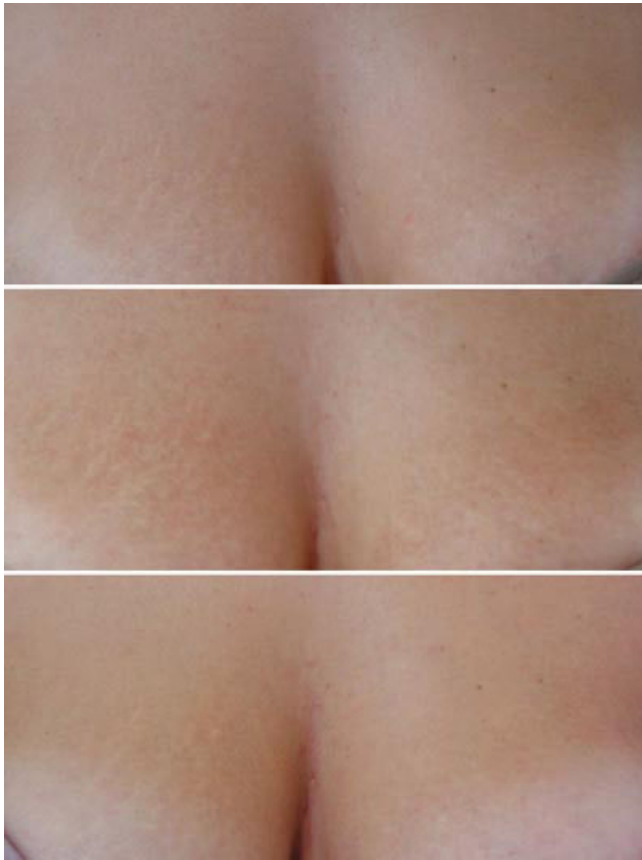

Fig. 3. **a:** Patient 3—before treatment. **b:** Patient 3—30 days after four sessions. **c:** Patient 3—18 months after four sessions (RF + retinoic acid + US).

Fig. 4. **a:** Patient 2—before treatment. **b:** Patient 2—30 days after four sessions (RF). **c:** Patient 2—18 months after four sessions (RF).

improvement; 2 = 26–50%—moderate improvement; 3 = 51–75%—marked improvement; 4 = 76–100%—excellent improvement [14].

Digital photographs (Sony DSC-H9—Super Steady Short 8.1 MP) were taken at baseline and at each follow-up visit to document clinical response. Statistical analyses were performed using Wilcoxon’s test. The significance level was set at $P < 0.05$. Data were analyzed using SPSS statistical software (IBM version 17.0).

RESULTS

All eight patients with SD on the breast, treated with the three-step procedure (RF + retinoic acid + US) showed global clinical improvement according to the scale used in this study without disagreement between the investigators evaluations. Three patients improved from 4 (severe) to 2 (moderate) (Fig. 2a–c); two patients improved from 4 (severe) to 1 (mild) (Fig. 3a–c); two patients from 2 (moderate) to 1 (mild); one patient from 3 (marked)

TABLE 4. Striae Distensae on the Breast: Severity Analysis Comparison Before and After Treatment With RF + Retinoic Acid + US

Final assessment	Total (%)	Baseline assessment		
		2 = Moderate	3 = Marked	4 = Severe
0 = None	0 (0.0)	0	0	0
1 = Mild	5 (62.5)	2	1	2
2 = Moderate	3 (37.5)	0	0	3
3 = Marked	0 (0.0)	0	0	0
4 = Severe	0 (0.0)	0	0	0
Total (%)	8 (100.0)	2 (25.0)	1 (12.5)	5 (62.5)

Note: P -value of Wilcoxon’s test = 0.008.

TABLE 5. Striae Distensa on the Abdomen: Severity Analysis Comparison Before and After Treatment With RF

Final assessment	Total (%)	Baseline assessment		
		2 = Moderate	3 = Marked	4 = Severe
0 = None	0 (0.0)	0	0	0
1 = Mild	1 (12.5)	0	1	0
2 = Moderate	1 (12.5)	0	1	0
3 = Marked	5 (62.5)	0	3	2
4 = Severe	1 (12.5)	0	0	1
Total (%)	8 (100.0)	0 0.0	5 (62.5)	3 (37.5)

Note: *P*-value of Wilcoxon's test = 0.125.

to 1 (mild). Clinical improvement was statistically significant ($P = 0.008$) (Table 4).

In the group treated with RF isolated (eight patients with SD on the abdomen), two patients improved from 4 (severe) to 3 (marked); one patient improved from 3 (marked) to 2 (moderate); and one patient improved from 3 (marked) to 1 (mild) (Fig. 4a–c). Four patients, one with severe SD and three with marked SD did not show any sort of improvement after treatment. Clinical improvement was not statistically significant (Table 5).

In the histopathological study, hematoxylin & eosin (H&E) stain showed disrupted skin by coagulation necrosis forming micro-channels (0.036 mm diameter average), within the epidermis, which reached the lowest layers of epidermis and the presence of the ink (black or green) distributed along the surface of epidermis in all samples of skin. In the case in which the patient was submitted to RF + ink (Fig. 5), the ink was present along the skin surface and inside the micro-channels. In the case in which the patient was submitted to RF + ink + US and biopsy just after procedure, the ink could also be observed along the skin surface but it was mainly located inside the micro-channels in the epidermis (Fig. 6). In the case in which the patient was submitted to RF + ink + US and

biopsy 30 minutes after procedure, the ink reached the dermo-epidermal junction (Fig. 7). There was not disagreement between the dermatopathologists.

Side effects including erythema and edema after procedure were considered mild to moderate in both groups of treatment (Fig. 8). Erythema persisted for 7–14 days after treatment. Dyschromia, blisters or scars did not occur in the group treated with RF + retinoic acid + US, but transitory hyperpigmentation occurred in one patient treated only with RF, lasting for 3 months. Moderate burning sensation was reported by all 16 patients during the procedure. This sensation reduced in a period of 12–24 hours.

All eight patients treated with the three-step procedure (RF + retinoic acid + US) were satisfied with the treatment and reported an improvement between 76% and 100% (“excellent improvement”). In the group treated with RF isolated, only three patients reported an improvement between 1% and 25% (“minimal improvement”) and five patients reported no improvement.

DISCUSSION

The therapeutic options for SD are numerous and no single treatment modality is markedly better than the others nor does any single modality consistently remove

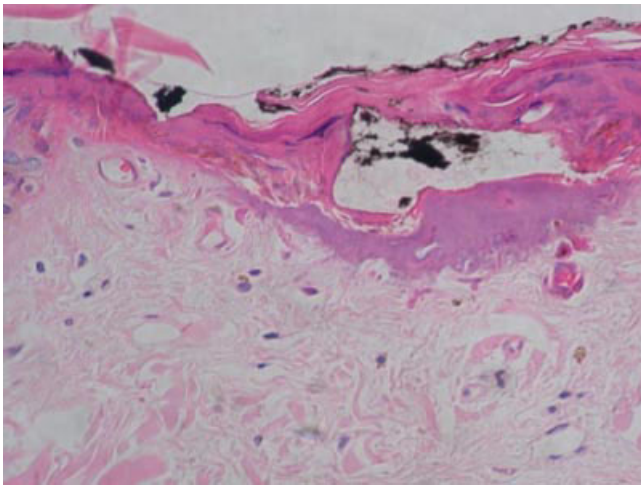


Fig. 5. Black ink along the skin surface and inside the micro-channels in the epidermis (HE 400×).

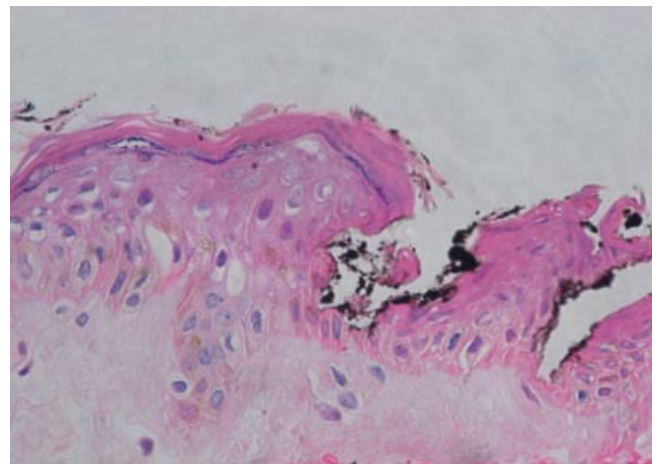


Fig. 6. Black ink mainly located inside the micro-channels in the epidermis (HE 400×).

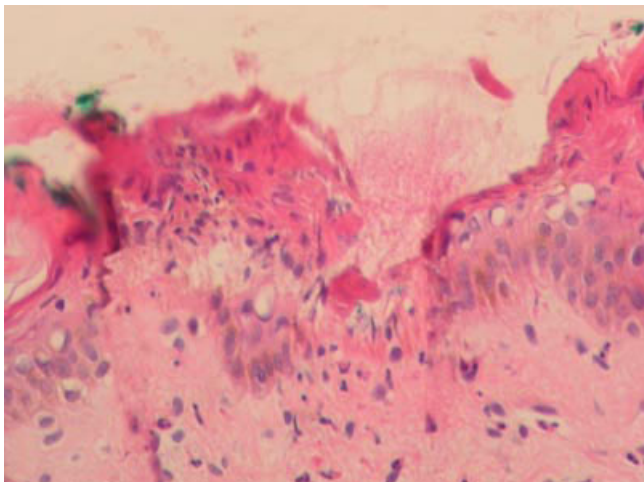


Fig. 7. Green ink inside the micro-channel reaching the dermal–epidermal junction (HE 400 \times).

SD completely. Multiple topical agents have been tried, including tretinoin, ascorbic acid, and glycolic acid but for only limited success, mainly for recent SD treatment. Non-laser light-based, abrasive and ultrasonic therapies, and more recently ablative and nonablative lasers have been reported to improve the appearance of SD [8].

Ablative resurfacing has been described as an option to mature SD treatment [3,6,7], although the use of ablative fractional methods with the aim to increasing drug delivery has been recently described in literature. This concept of TED was described in some studies with animal's skin reported by Gómez et al. [11], in 2008, with 5-fluorouracil after Er:YAG laser and by Haerdersdal et al. [12], in 2010, with methyl aminolevulinate after CO₂ laser. TED using ablative fractional RF associated with acoustic

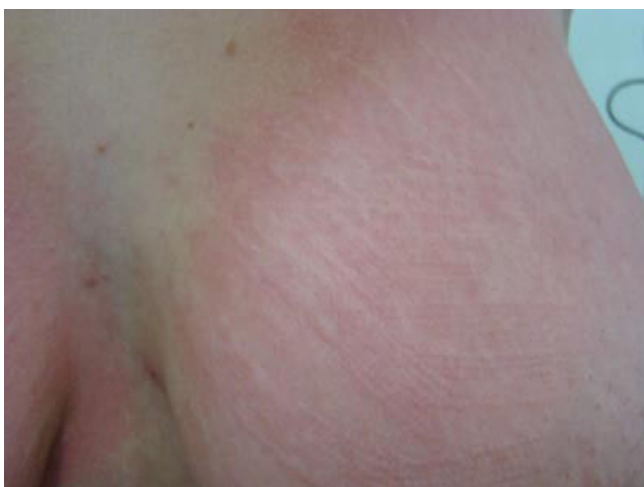

Fig. 8. Patient 3—severe erythema immediately after treatment.

pressure US to improve methyl aminolevulinate penetration before red light illumination has recently been reported in multiple actinic keratosis treatment for immunosuppressive and immunocompetent patients [15,16]. Lately the same technique has been used to improve triamcinolone penetration in hypertrophic scars with excellent results (Int J Dermatol Mar 27, 2012 [Epub ahead of print]).

This study, to our knowledge, is the first study using the combination of physical methods—ablative fractional method and acoustic pressure US for the treatment of SD. The ablative fractional method used was RF which created microchannels on the skin surface and the acoustic pressure US was applied with the aim to pushing the retinoic acid through these channels into the skin. According to what has been published in literature regarding SD treatment [1,5,6,9] and based on our first studies about TED (RF + US) associated with photodynamic therapy for actinic keratosis treatment [16] and TED (RF + US) in hypertrophic scar treatment (Int J Dermatol Mar 27, 2012 [Epub ahead of print]), the use of ablative fractional RF and acoustic pressure US associated with retinoic acid 0.05% showed a good result and can be considered a new method for mature SD treatment. We have treated eight patients with SD on the abdomen in order to evaluate the clinical response of RF isolated in SD treatment. Despite of that, the number of patients enrolled in this study is not enough to make statistical analyses comparing the RF isolated treatment to RF + retinoic acid + US.

CONCLUSION

Ablative fractional RF and acoustic pressure US technology used as a method to increase retinoic acid cream permeability resulted in a significant clinical improvement in the appearance of alba-type SD on the breast area with low incidence of side effects and high level of patient's satisfaction. Ablative fractional RF isolated in the treatment of the alba-type SD on the abdomen showed a poor clinical result with low incidence of side effects but low level of patient's satisfaction.

The combination of RF + US technology for the purpose of TED therapy is a promising modality for enhancing therapeutic outcomes in alba-type SD.

REFERENCES

1. Elsaie ML, Baumann LS, Elsaiee LT. Striae distensae (stretch marks) and different modalities of therapy: An update. *Dermatol Surg* 2009;35(4):563–573.
2. Bak H, Kim BJ, Lee WJ, Bang JS, Lee SY, Choi JH, Chang SE. Treatment of striae distensae with fractional photothermolysis. *Dermatol Surg* 2009;35(8):1215–1220.
3. Tay YK, Kwok C, Tan E. Non-ablative 1,450-nm diode laser treatment of striae distensae. *Lasers Surg Med* 2006;38(3):196–199.
4. Goldman A, Rossato F, Prati C. Stretch marks: Treatment using the 1,064-nm Nd:YAG laser. *Dermatol Surg* 2008;34(5):686–691.
5. Jiménez GP, Flores F, Berman B, Gunja-Smith Z. Treatment of striae rubra and striae alba with the 585-nm pulsed-dye laser. *Dermatol Surg* 2003;29(4):362–365.
6. Nouri K, Romagosa R, Chartier T, Bowes L, Spencer JM. Comparison of the 585 nm pulse dye laser and the short

- pulsed CO₂ laser in the treatment of striae distensae in skin types IV and VI. *Dermatol Surg* 1999;25(5):368–370.
7. Suh DH, Chang KY, Son HC, Ryu JH, Lee SJ, Song KY. Radiofrequency and 585-nm pulsed dye laser treatment of striae distensae: A report of 37 Asian patients. *Dermatol Surg* 2007;33(1):29–34.
 8. McDaniel DH. Laser therapy of stretch marks. *Dermatol Clin* 2002;20(1):67–76.
 9. Stotland M, Chapas AM, Brightman L, Sukal S, Hale E, Karen J, Bernstein L, Geronemus RG. The safety and efficacy of fractional photothermolysis for the correction of striae distensae. *J Drugs Dermatol* 2008;7(9):857–861.
 10. Kim BJ, Lee DH, Kim MN, Song KY, Cho WI, Lee CK, Kim JY, Kwon OS. Fractional photothermolysis for the treatment of striae distensae in Asian skin. *Am J Clin Dermatol* 2008;9(1):33–37.
 11. Gómez C, Costela A, García-Moreno I, Llanes F, Teijón JM, Blanco D. Laser treatments on skin enhancing and controlling transdermal delivery of 5-fluorouracil. *Lasers Surg Med* 2008;40(1):6–12.
 12. Haedersdal M, Sakamoto FH, Farinelli WA, Doukas AG, Tam J, Anderson RR. Fractional CO₂ laser-assisted drug delivery. *Laser Surg Med* 2010;42(2):113–122.
 13. Walgrave SE, Ortiz AE, MacFalls HT, Elkeeb L, Truitt AK, Tournas JA, Zelickson BD, Zachary CB. Evaluation of a novel fractional resurfacing device for treatment of acne scarring. *Lasers Surg Med* 2009;41(2):122–127.
 14. Stotland M, Chapas AM, Brightman L, Sukal S, Hale E, Karen J, Bernstein L, Geronemus RG. The safety and efficacy of fractional photothermolysis for the correction of striae distensae. *J Drugs Dermatol* 2008;7(9):857–861.
 15. Chevrand NS, Kassuga LEPP, Issa MCA. Transepidermal drug delivery to increase photodynamic therapy. In: ASLMS Annual Meeting of the American Society for Laser Medicine and Surgery, Kissimee, April 2012. p. 56; Abstract.
 16. Kassuga LEPP, Issa MCA, Chevrand NS. Transepidermal application of medication combined with photodynamic therapy in the treatment of actinic keratosis. *Surg Cosmet Dermatol* 2012;4(1):89–92.